



BASIC GUIDELINES ON WHEN TO REMOVE A PLAYER FROM THE FIELD OF PLAY FOLLOWING A SHOULDER INJURY

Dr Joe de Beer

Cape Shoulder Institute,
43 Blouelie Crescent,
Platteklouf,
Cape Town,
Tel: (021) 911 1017
Fax: (021) 911 1019
shoulder@iafrica.com
www.shoulderinstitute.co.za



Providing coaches, referees, players, and administrators with the knowledge, skills, and leadership abilities to ensure that safety and best practice principles are incorporated into all aspects of contact rugby.

INTRODUCTION

An increase in the frequency and severity of shoulder injuries in rugby has been noted and this realisation has prompted guidelines such as this one to be drawn up as a guide for the coaches, physiotherapists and sport physicians caring for the players on the field^(3, 10, 1, 22, 15, 4). Of equal importance is that younger players are playing more competitively and aggressively and the specific injury patterns in these players with immature skeletal structures should be realised^(13, 2, 7, 22).

BASIC ANATOMY (FIG. 1)

The most relevant structures of the shoulder to recognise as far as injuries are concerned are:

Trapezius muscle

The trapezius is the large muscle running from the neck to the shoulder and neck

Acromio-clavicular (AC) joint

This is the junction between the collar bone and shoulder bone

Deltoid muscle

The large muscle at the upper and outer aspect of the arm which is the main muscle used to lift the arm

Rotator cuff tendon

This is also an important muscle and tendon to lift the arm and is situated deep to the deltoid

Sterno-clavicular (SC) joint

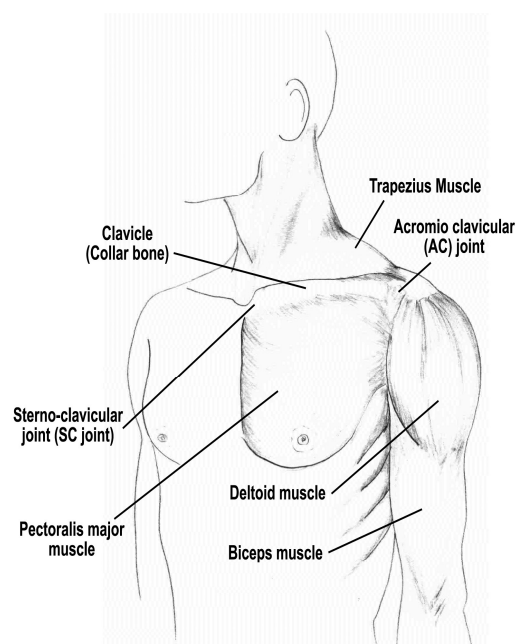
The junction between the breast bone and collar bone on the upper front part of the chest

Brachial plexus

The large set of nerves above the collar bone, which run from the neck to the shoulder and arm

Shoulder joint (Gleno-humeral joint)

This is the main ball and socket of the shoulder



(Fig.1) SUPERFICIAL ANATOMY

Pectoralis major (Pec Major)

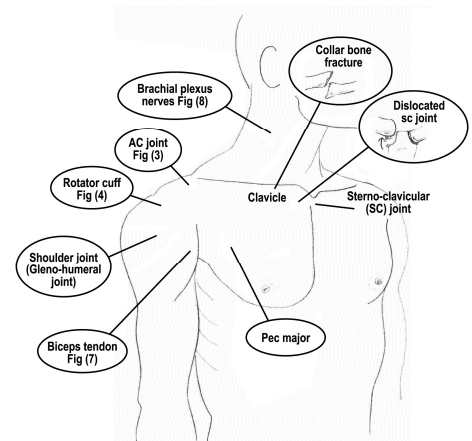
The large muscle on the chest which draws the arm towards the body

Clavicle (collar bone)

The collar bone supports the shoulder and can easily be felt under the skin

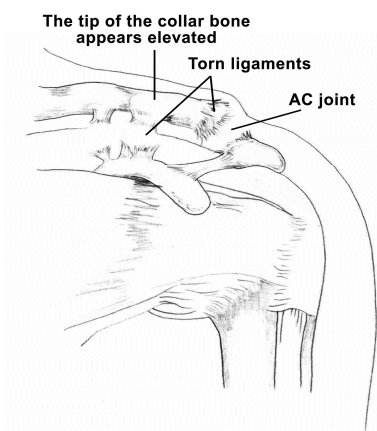
STRUCTURES MOST OFTEN INJURED (FIG 2)

Soft tissue around the shoulder: In the game of rugby direct blows are common and soft tissue bruising of the trapezius muscle, the deltoid, the pec major and other soft tissue around the shoulder is usually not of long-term significance for the player.



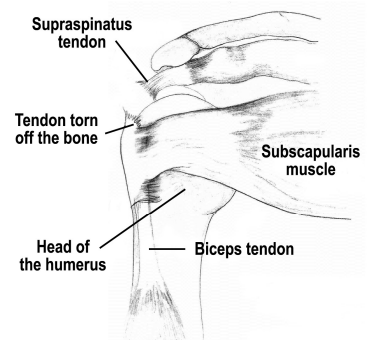
(Fig.2) ANATOMY
Location of structures as seen from outside

AC joint: (Fig 3): This junction between the collar bone and shoulder bone is one of the most commonly injured structures during rugby games. It usually results from a fall directly onto the shoulder – usually slightly towards the back of the shoulder. This may result in either a sprain or an actual dislocation of this joint due to a rupture of the ligaments stabilising the AC joint ^(20, 21).



(Fig.3) ACROMIO-CLAVICULAR (AC) JOINT DISLOCATION

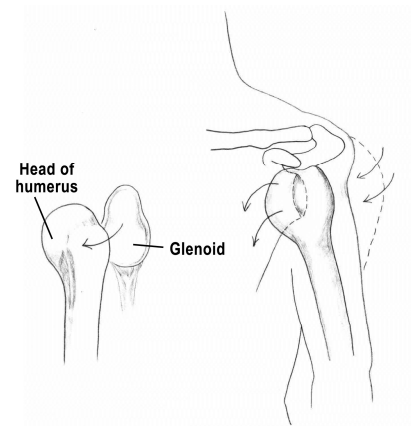
Rotator cuff (Fig 4): The rotator cuff tendon, deep to the deltoid, is commonly injured when the abducted or extended arm is forced downwards or backwards especially during a fall or a tackle. The injury may be a simple strain or a frank tear of the tendon. The latter is rare in young players and usually a strain of the tendon is more common.



(Fig.4) ROTATOR CUFF TEAR (SUPRASPINATUS TEAR)

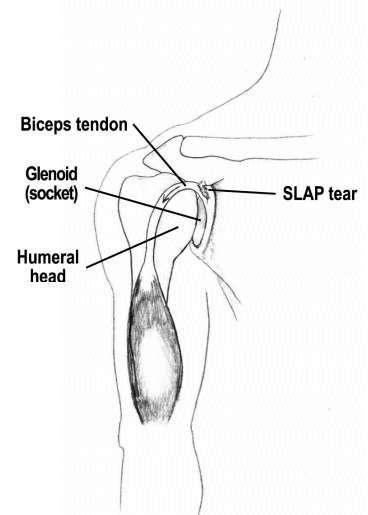
SC joint (Fig 2): The junction between the breast bone and collar bone (upper front of the chest) is injured when the player falls directly onto the shoulder. The joint may be painful with swelling or dislocated ⁽¹⁶⁾.

Shoulder Joint: (Fig 5) The shoulder joint itself (ball and socket) may be injured during a direct fall and often when the arm is forced outwards and backwards. This may result in injuries to the labrum and ligaments. The stabilising ligaments of the shoulder attach to the rim of the socket called the labrum. If the labrum simply tears, the injury is referred to as a Bankart lesion. If the force is great enough the shoulder might actually dislocate. Shoulder dislocations in rugby are a frequent injury. The ligament may also be torn off the humeral head and is referred to as a HAGL lesion. Another injury which could occur inside the joint is a bruise of the joint surface ("bone bruise") which may be sustained during a direct blow on the shoulder ⁽¹²⁾.



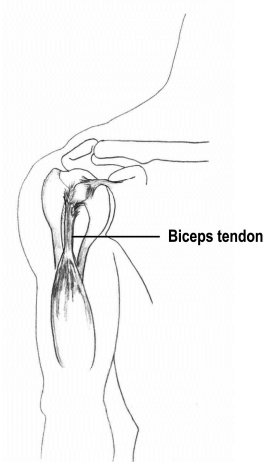
(Fig.5) SHOULDER DISLOCATION

SLAP lesions ("Superior Labrum Anterior to Posterior") (Fig 6): These are tears of the top part of the cartilage surrounding the glenoid (socket) of the shoulder joint. They may be caused by a fall on to the elbow with an upward force into the shoulder joint ⁽⁹⁾



(Fig.6) SLAP lesion
(Torn superior labrum)

Biceps tendon (Fig 7): The long head of the biceps muscle may be injured by traction forces on the biceps and may even be ruptured.



(Fig.7) BICEPS
Tendon: Swollen or frayed out or even torn

Fractures: In adult players, fractures around the shoulder joint are rare but do occur with regular frequency in young schoolboy players. The cartilage growth plates of the upper humerus and the collar bone are most involved ^(13, 2).

MECHANISMS OF INJURY MOST COMMONLY SEEN IN RUGBY

The most common mechanism of injuries are:

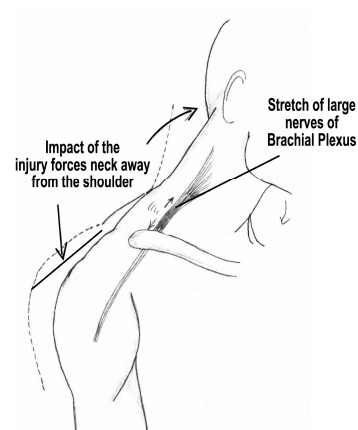
Direct blow to the shoulder: This may happen when a player impacts on the shoulder from either the front or the back. This may result in simple bruising of the shoulder or even dislocation.

Falls directly onto the shoulder with the arm by the side: AC joint injuries often occur due to this mechanism – direct falls onto the shoulder often result in AC joint sprain or dislocation. In some instances rotator cuff injuries may also occur due to this mechanism.

Rotator cuff injuries: These usually occur when the arm is forced downward when it is held up forwards or to the side or even from a fall onto the shoulder.

Shoulder dislocation: The usual mechanism is when the arm is forced outwards and backwards. This would happen during a “straight arm tackle” or when another player falls onto the back of the shoulder forcing the upper arm backwards ⁽¹⁾.

Brachial plexus injuries (Fig 8): These usually happen when the head is forced away from the shoulder and the shoulder is pushed downwards – the result is a severe stretch of the tissues between the shoulder and neck. This would happen when a player falls forward and downwards, contacting the arm and the head at the same time. This leads to a stretch of the big nerve above the collar bone (brachial plexus) ⁽¹⁷⁾.



(Fig.8) BRACHIAL PLEXUS (NERVE) STRETCH INJURY

AC joint: This joint is usually injured with a direct fall onto the shoulder.

Pec Major tears (Fig 9): This powerful muscle is very rarely torn. However, the muscle is at risk in rugby when a forward has his arm engaging another player in a scrum. When the scrum collapses the contracting muscle gets stretched out and away from the body and may result in a tear of the pec major ^(18, 8).

Collar bone: This fracture occurs during a direct fall onto the shoulder, but this is less common in rugby.

After injuring a shoulder the relevant medical or other attendants would assess the shoulder in the following manner. This assessment will lead to a decision as to the immediate further management:

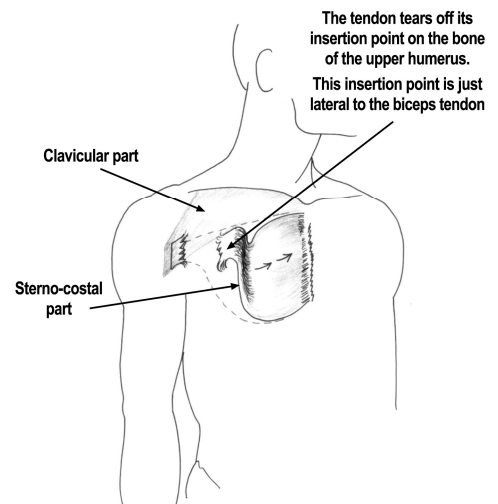


Fig 9. A tear of the sterno costal part of the Pec major muscle. This part tears more commonly than the clavicular part. In rare instances both parts may tear together.

Obvious bruising or deformity

Swelling or deformity over the AC joint – this may indicate an AC joint injury / dislocation

Bruising or swelling over the trapezius or deltoid – this may be soft tissue bruising of these muscles

Pain inside the joint – this may be a labral or rotator cuff injury

Deformity of the joint itself with inability to move it – this is usually due to a dislocation of the shoulder joint

Obvious rupture of the pec major – a bulge will be seen over the pec major area with a bruising in the upper arm

GUIDELINES ON WHEN TO REMOVE THE PLAYER FROM THE FIELD FOLLOWING A SHOULDER

INJURY:

If the shoulder is obviously dislocated the player is removed and is managed by the medical practitioner on the side of the field or referred to a hospital for reduction of the dislocation.

Deformity over the AC joint: pain can be the determining factor. Should the player be able to continue he may do so without any serious effects. On the other hand, should his pain be of such a nature that he

is not able to play competently, he will be removed. Trying to play on does not have any serious deleterious effect though ^(20, 21).

Deeper injuries of the rotator cuff and labrum: These may not be visible from the surface and a simple test would be to ask the player to lift his arm. If he can do this comfortably, there is no immediate indication to remove him off the field and he could be allowed to play if pain allows him to. If, however, he is unable to elevate the arm he should be removed from the field.

Collar bone: If severe pain and deformity is evident over the collar bone this may be a fracture and he should be removed for further medical attention.

Brachial plexus injuries: This is referred to as a “burner” or “stinger”. The neck and the shoulder are often forced away from each other during a fall – this results in a stretch of the nerves of the brachial plexus with immediate burning pain and inability to move the arm. The player should be removed for confirmation of the injury by the medical attendants. ⁽¹⁷⁾

SC injury: Often the player points to a painful lump at the medial (inner) side of the collar bone at the upper part of the chest. If pain is not severe the player often continues and it is noteworthy that many players only present with these injuries after the game. Some of these SC joint injuries may be more serious and in general it is advised that the player be removed for medical assessment. ⁽¹⁶⁾

Biceps tendon injury/rupture: Although further damage with continued play is unlikely the pain following the injury will usually be too intense to allow continuation.

Pec major rupture: Pec major rupture often goes unnoticed as the pain may be brief as the tendon tears off its insertion. The player could continue as there is not an immediate indication for removal off the field but soon after the match he should be referred for an assessment.

FURTHER MANAGEMENT OF SPECIFIC INJURIES FOLLOWING THE RUGBY MATCH:

Soft tissue injuries: These could be treated conservatively by physiotherapists.

AC joint injuries: These seldom, if ever, require immediate surgical intervention and can usually be managed conservatively by the physiotherapist and attending physician. Surgery is seldom, if ever, necessary in the acute phase and a rare few may require it in the longer run ⁽²¹⁾.

Rotator cuff injuries: The majority of rotator cuff injuries in rugby players are strains / tendonitis. These could be managed conservatively by the physiotherapist and medical attendants and may require a cortisone injection on some occasions. If a rotator cuff tear (which is rare in these young players) is

suspected referral to a specialist may become indicated to verify the extent of the injury and possible surgical repair. ⁽¹¹⁾

Shoulder dislocations: After the shoulder has initially been reduced, referral to a specialist is preferable to exclude significant damage: labral tears and bony lesions of the glenoid may need to be addressed and not infrequently surgery could be indicated. ^(5, 6, 20)

Brachial plexus injuries: If such an injury is diagnosed by the attending medical officer, referral to a neurologist may be indicated to confirm the extent and prognosis of the injury.

Clavicle fracture: This would require referral for a specialist opinion to gain an opinion on the severity and indicated management for the problem. Not all of these fractures need to be operated but it would be best for the specialist to decide on further management.

Pec Major rupture: This injury would require referral for specialist opinion as many of them may require surgical repair. ^(18, 8)

CONCLUSION

With the appropriate management of shoulder injuries in rugby players, most of the players should be able to return to the sport and not suffer long-term effects on the well-being of this important joint.

AUTHOR'S BIOGRAPHY

Dr Joe de Beer is an internationally recognized surgeon, who is dedicated to the management of problems of the shoulder. He has lectured and published widely and has a keen interest in the shoulder injuries suffered by rugby players. He has successfully treated large numbers, including many of our professional players.

REFERENCES

1. Bhatia DN, de Beer JF, van Rooyen KS, du Toit DF. The reverse terrible triad of the shoulder: circumferential glenohumeral musculoligamentous disruption and neurologic injury associated with posterior shoulder dislocation. *J Shoulder Elbow Surg.* 2007 May-Jun;16(3):e13-7. Epub 2007 Mar 26.
2. Bowman TG, Palmieri-Smith R. Proximal humeral epiphyseal plate fracture in a collegiate track and field decathlete: a case study. *J Sport Rehabil.* 2008 Feb;17(1):76-83.

3. Brooks JH, Kemp SP. Recent trends in rugby union injuries. *Clin Sports Med.* 2008 Jan;27(1):51-73, vii-viii
4. Brooks JH, Fuller CW, Kemp SP, Reddin DB. Epidemiology of injuries in English professional rugby union: part 2 training Injuries. *Br J Sports Med.* 2005 Oct;39(10):767-75.
5. Burkhart SS, De Beer JF, Barth JR, Cresswell T, Roberts C, Richards DP. Results of modified Latarjet reconstruction in patients with anteroinferior instability and significant bone loss. *Arthroscopy.* 2007 Oct;23(10):1033-41. Erratum in: *Arthroscopy.* 2007 Dec;23(12):A16. Criswell, Tim [corrected to Cresswell, Tim].
6. Burkhart SS, De Beer JF. Traumatic glenohumeral bone defects and their relationship to failure of arthroscopic Bankart repairs: significance of the inverted-pear glenoid and the humeral engaging Hill-Sachs lesion. *Arthroscopy.* 2000 Oct;16(7):677-94.
7. Collins CL, Micheli LJ, Yard EE, Comstock RD. Injuries sustained by high school rugby players in the United States, 2005-2006. *Arch Pediatr Adolesc Med.* 2008 Jan;162(1):49-54.
8. Dodds SD, Wolfe SW. Injuries to the pectoralis major. *Sports Med.* 2002;32(14):945-52.
9. Funk L, Snow M. SLAP tears of the glenoid labrum in contact athletes. *Clin J Sport Med.* 2007 Jan;17(1):1-4.
10. Headey J, Brooks JH, Kemp SP. The epidemiology of shoulder injuries in English professional rugby union. *Am J Sports Med.* 2007 Sep;35(9):1537-43. Epub 2007 Apr 23.
11. Huijsmans PE, Pritchard MP, Berghs BM, van Rooyen KS, Wallace AL, de Beer JF. Arthroscopic rotator cuff repair with double-row fixation. *J Bone Joint Surg Am.* 2007 Jun;89(6):1248-57.
12. Jeon IH, Wallace WA. Traumatic humeral articular cartilage shear (THACS) lesion in a professional rugby player: a case report. *Br J Sports Med.* 2004 Aug;38(4):E12.
13. Lampasi M, Bochicchio V, Bettuzzi C, Donzelli O. Sternoclavicular physeal fracture associated with adjacent clavicle fracture in a 14-year-old boy: a case report and literature review. *Knee Surg Sports Traumatol Arthrosc.* 2008 Feb 19. [Epub ahead of print]
14. Lee AJ, Garraway WM, Hepburn W, Laidlaw R. Influence of rugby injuries on players' subsequent health and lifestyle: beginning a long term follow up. *Br J Sports Med.* 2001 Feb;35(1):38-42.

15. McIntosh AS. Rugby injuries. *Med Sport Sci.* 2005;49:120-39.
16. Mirza AH, Alam K, Ali A. Posterior sternoclavicular dislocation in a rugby player as a cause of silent vascular compromise: a case report. *Br J Sports Med.* 2005 May;39(5):e28.
17. Perlmutter GS, Leffert RD, Zarins B. Direct injury to the axillary nerve in athletes playing contact sports. *Am J Sports Med.* 1997 Jan-Feb;25(1):65-8.
18. Potter BK, Lehman RA Jr, Doukas WC. Pectoralis major ruptures. *Am J Orthop.* 2006 Apr;35(4):189-95. Review.
19. Quinn DI. Dissecting the rugby tackle: do shoulder pads contribute to cervical spine injuries? *Med J Aust.* 1998 Nov 2;169(9):501-2.
20. Robinson CM, Jenkins PJ, White TO, Ker A, Will E. Primary arthroscopic stabilization for a first-time anterior dislocation of the shoulder. A randomized, double-blind trial. *J Bone Joint Surg Am.* 2008 Apr;90(4):708-21.
21. Trainer G, Arciero RA, Mazzocca AD. Practical management of grade III acromioclavicular separations. *Clin J Sport Med.* 2008 Mar;18(2):162-6.
22. Yard EE, Comstock RD. Injuries sustained by rugby players presenting to United States emergency departments, 1978 through 2004. *J Athl Train.* 2006 Jul-Sep;41(3):325-31.

